



PRESENTING CLINICAL SIGNS

History: Grade II/VI murmur. Suspected syncopal episode. History of epilepsy.

DATE

10/12/22

ECHOCARDIOGRAPHIC FINDINGS

2D, M-mode, and Doppler study.

PERFORMED BY:

Shari Reffi, CVT

Left atrial size is normal. The mitral valve appears normal, though trace mitral regurgitation is present. Left ventricular dimensions are normal. Left ventricular systolic function is hyperdynamic. The aorta and aortic valve are normal. Right atrial and right ventricular dimensions are normal. The tricuspid valve is normal. The pulmonary artery and pulmonic valve are normal. No shunting lesions are visualized. No pericardial effusion or cardiac masses are seen.

INTERPRETED BY

Keith Blass, DVM,
MS, DACVIM
(Cardiology)

LA - 23.7 mm
LVIDd - 23.4 mm
LVIDs - 12.0 mm
FS - 48.7%
RA - 17.3 mm
LVOT - 1.34 m/s
RVOT - 1.33 m/s

PATIENT

Emma Cawthorne

ASSESSMENT/RECOMMENDATIONS

Normal echocardiogram

SPECIES

Canine

This examination demonstrates no evidence of structural heart disease, as trace regurgitation of blood across Emma's mitral valve can be considered a normal physiologic variant. As such, no reason for Emma's suspected syncopal episode is appreciated in the image set. If syncope, rather than seizure activity, did occur, likely differentials include a vasovagal reflex and an arrhythmia.

BREED

Maltese

No therapy is recommended based on this exam.

An ECG and/or Holter/event monitor is recommended if Emma experiences additional syncopal-like episodes. A recheck echocardiogram is recommended if the characteristics of Emma's murmur change, or if other new physical exam and/or clinical abnormalities suggestive of cardiac dysfunction develop.

SEX

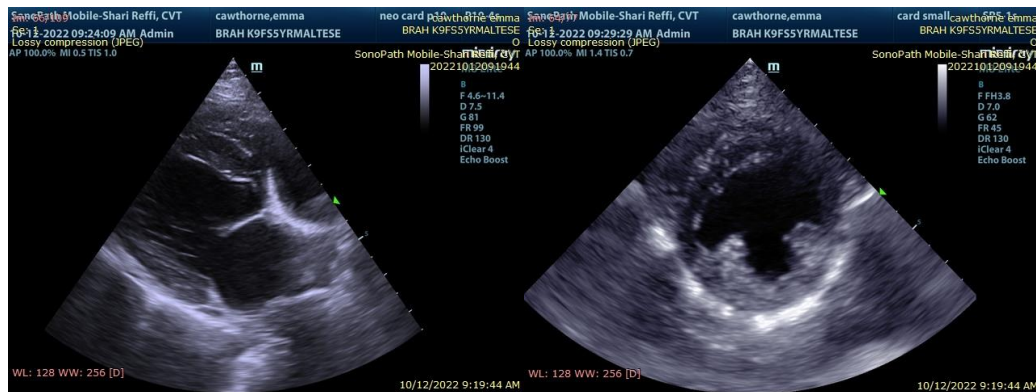
FS

AGE

5 y

WEIGHT

14.1 lb



HOSPITAL NAME

Basking Ridge AH

REFERRING VET

Dr. Hollo

The information and recommendations provided are based on the images presented by the referring veterinarian. No evaluation can be communicated regarding pathology that was not visible in the image/video clips provided.



Thank you for this referral. If the clinical or image interpretation does not parallel your findings or if I can be of any further assistance please contact me.

DATE

10/12/22

Keith Blass, DVM, MS, DACVIM (Cardiology)
KeithBlass@gmail.com
631-804-5754

PERFORMED BY:

Shari Reffi, CVT

INTERPRETED BY

Keith Blass, DVM,
MS, DACVIM
(Cardiology)

PATIENT

Emma Cawthorne

SPECIES

Canine

BREED

Maltese

SEX

FS

AGE

5 y

WEIGHT

14.1 lb

HOSPITAL NAME

Basking Ridge AH

REFERRING VET

Dr. Hollo